

Imaging the Paediatric Airway



Laura Coleman, MRCP,
Specialist Registrar in Radiology



Helen Williams, FRCR,
Consultant Paediatric Radiologist



Kate Parkes,
Radiology Clinical Systems Manager



Michael Kuo, FRCS,
Children's Ear, Nose and Throat Surgeon

Correspondence
Michael Kuo,
Children's Ear,
Nose and Throat Surgeon,
Birmingham Children's Hospital,
Steelhouse Lane,
Birmingham B4 6NH, UK.
E: michael.kuo@mac.com

Declaration of Competing Interests
None declared.

Multidisciplinary co-operation in the assessment of the paediatric airway is essential to the safe management of infants and children with respiratory compromise. This article is not intended to be a comprehensive atlas of airway anomalies but seeks to illustrate some of the situations where high quality imaging is central to diagnosis and management.

General considerations in radiology

Many aspects of current imaging, such as Computed Tomography (CT) and Magnetic Resonance Imaging (MRI), require a degree of patient co-operation and control in order to obtain adequate images. However, with a young child, especially those with developmental delay, this may not be possible. Therefore sedation and general anaesthesia have to be considered. Sedation can produce excellent results, avoiding invasive procedures, but requires careful monitoring at all times (respiratory rate, oxygen saturation). It poses the risk of destabilising the airway, increasing the risk of aspiration and causing respiratory compromise. Therefore only suitable candidates must be chosen and resuscitation equipment needs to be close by. Multidetector spiral CT is often used in paediatric imaging due to its faster acquisition times, reduction in ionising radiation exposure and ability to produce better 3D image reconstructions. Faster scanning helps to reduce movement artefact which is of particular benefit with a paediatric population who can't necessarily follow instructions and co-operate with, for example, breath-holding.

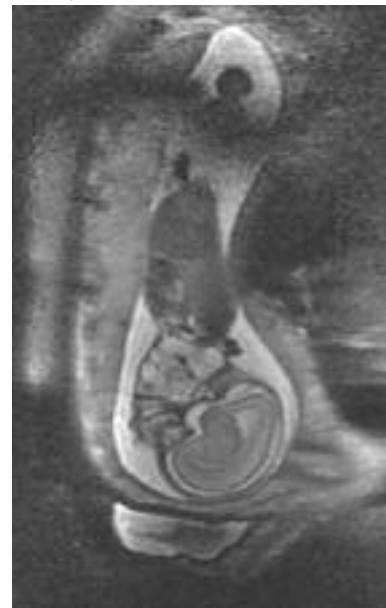If there is any risk of destabilising the airway in a child, especially one with known or suspected airway abnormality, then general anaesthesia is by far the safest option. It is important to remember that neonates and young infants are obligate nasal breathers, so any form of nasal airway obstruction can lead to acute respiratory compromise. Airway control aided by general anaesthesia is best considered on a planned basis rather than as an emergency procedure in the CT or MRI suite. It should be carried out and closely supervised by a fully trained paediatric anaesthetist. Care must be taken to use MRI compatible equipment when necessary.

Foetal imaging

Rapid improvements in ultrasound technology, particularly in improved image resolution, have facilitated the diagnosis of more complex disorders. Of particular relevance to the airway are the diagnoses of neck / thoracic masses causing compression of the airway and disease entities such as laryngeal atresia, both needing immediate intervention at birth. Apart from ultrasound visualisation of mass lesions, polyhydramnios picked up on foetal ultrasound may be an indirect indicator of possible foetal airway abnormalities, prompting further investigation.

Where a mass lesion is detected in the neck, foetal MRI can be used to further define the mass, contributing to the differential diagnosis as well as defining its relationship to the airway (Figure 1). This aids the obstetrician and the paediatric airway surgeon in counselling the prospective parents particularly with respect to airway

Figure 1: Sagittal T2 weighted foetal MRI image showing mass in the anterior neck.



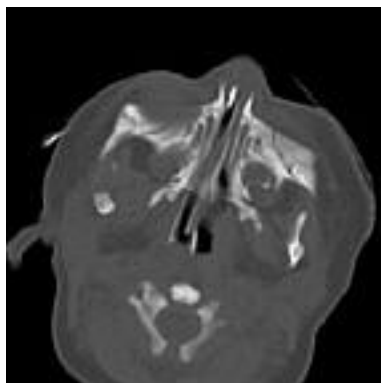


Figure 2A: Axial CT scan showing congenital piriform aperture stenosis.

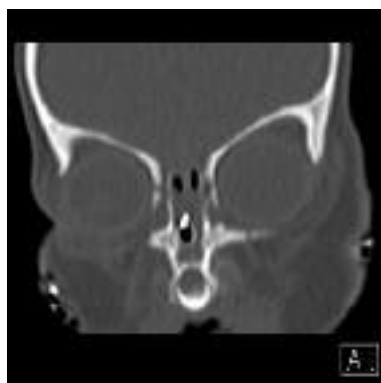

Figure 2B: Coronal CT scan of same patient showing single incisor associated with congenital piriform aperture stenosis.

management during delivery and the appropriateness of an ex-utero intra-partum therapy (ExIT) procedure.

Nasal airway pathology of infancy

Neonates are obligate nasal breathers for the first few months of life and significant nasal obstruction results in respiratory distress, apnoea and cyanosis. Less acutely, it may manifest itself as difficulty feeding and a failure to thrive. The paediatric otolaryngologist may be asked to review a child in whom it has been impossible to pass a nasogastric tube down one nostril to assess for unilateral choanal atresia. The availability of fine neonatal endoscopes (1.8mm) allows endoscopic examination, but CT remains the modality of choice for defining bony anatomy and is able to highlight the absence of nasal bones as well as the presence and thickness of bony atresia plates. Three-dimensional CT imaging can be used for planning nasal reconstruction / reconstruction surgery in those paediatric patients who are developmentally normal or near normal.

Multiplanar CT or MRI is used to assess the intracranial contents in order to aid prognosis. MRI provides more detailed neuroanatomy and is able to confirm the

presence or absence of the olfactory nerves.

Congenital anterior piriform aperture stenosis / central midline incisor syndrome arises from overgrowth of the nasal process of the maxilla, narrowing the nasal piriform aperture and is an uncommon cause of upper airway obstruction in the neonate. Clinically, there is a narrowing of the anterior choana. CT demonstrates a narrowed anterior nasal cavity: piriform aperture <8mm diameter including nasal septum and single anterior nare width <2mm (Figures 2A and 2B). Features which may also be present include a hypoplastic triangular-shaped palate, bony overgrowth of the maxillary nasal process, incisor abnormalities – a single central midline incisor or partial central incisor fusion. It is important to image the intracranial contents of these patients due to the risk of other midline abnormalities. An MRI head scan in these patients will identify the presence or absence of associated intracranial midline abnormalities including holoprosencephaly, posterior pituitary ectopia, medial deviation of the cavernous carotids and Chiari I malformation.

Posterior choanal stenosis / atresia is caused by defective development of the oronasal membrane at the level of the

posterior choanae. Computed Tomography is the imaging modality of choice in determining whether there is choanal atresia or just stenosis, whether it is unilateral or bilateral and for surgical preparation, whether an atresia is membranous, bony or mixed. Sedation is contraindicated in infants with bilateral disease and airway intubation under general anaesthesia is essential. The patient needs to have nasal suction and instillation of vasoconstrictive nasal drops pre-scan. High resolution axial scans with multiplanar reconstruction are obtained. Axial and coronal views help to demonstrate the presence or absence of a complete bony bridge. Computed Tomography features of posterior choanal stenosis / atresia include a narrowed or funnel shaped posterior nasal cavity, medial deviation of the posterior maxilla, lateral deviation and thickening or splitting of the posterior vomer, fusion or bridging of the vomer to the maxilla, complete or partial obstruction of the posterior choanae by a bony bridge or soft tissue membrane (choana <3.5mm diameter), air-fluid level within the obstructed nasal cavity, elevation of the ipsilateral hard palate and hypoplasia of the inferior turbinates. Observation of these features prepares the surgeon for the operative approach.

Where choanal atresia is diagnosed, high resolution CT imaging of the petrous bone should be performed at the same time, if possible, especially in infants with bilateral disease due to the high incidence of CHARGE syndrome in this population (coloboma, heart defects, atresia choanae, retarded growth / development, genital hypoplasia, ear anomalies)(Figures 3A and 3B).

Radiology and the assessment of stridor in children

The majority of children presenting with stridor will require direct visualisation of

Figure 3A: Bilateral mixed bony-membranous choanal atresia.

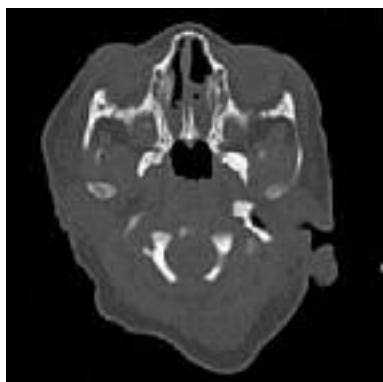
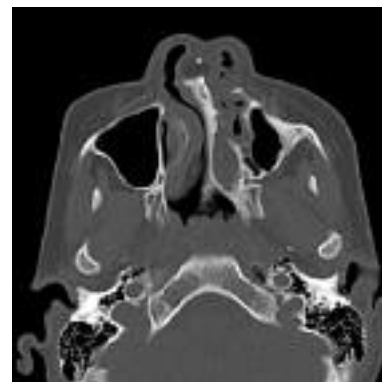
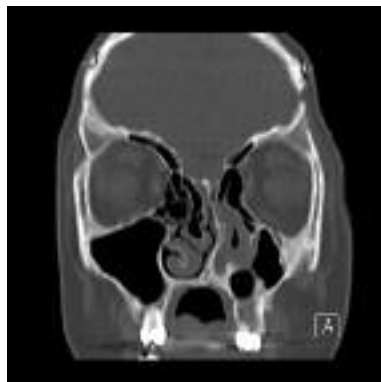Figure 3B: These images show coronal / axial images of unilateral left bony choanal atresia.



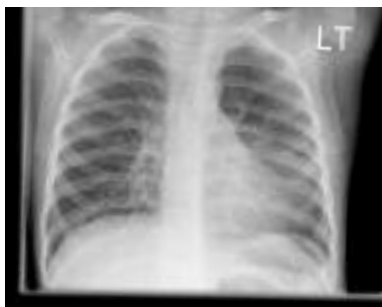

Figure 4: Plain radiograph showing the 'steeples' sign in acute laryngotracheobronchitis.

the airway with either flexible or rigid endoscopy. However, radiology provides a useful adjunct to this and can give invaluable additional information during both diagnosis and follow-up which aids the appropriate management of the patient.

Plain radiography

Frontal (anteroposterior) and lateral views of the neck help to demonstrate airway calibre and outline important anatomical landmarks. However, they can be misleading as small variations in patient position can dramatically alter the appearances on the film and radiographs are not performed as a routine in clinical practice. The high-kV 'Cincinnati' view is not used as frequently today as in the past due to the improvement in image quality obtained with modern-day computed radiography.

Plain radiographs are helpful in demonstrating adenoidal hypertrophy and the effect on the nasopharyngeal airway in *obstructive sleep apnoea*. The upper limit of normal adenoid size is 12mm AP diameter. Enlarged palatine tonsils may also be seen.

Plain film imaging of the child with acute stridor has fallen out of favour because it is considered dangerous, especially out of hours, to take a child with a marginal airway away from the resuscitation room and into an environment which the child may find intimidating. The diagnosis of the child with acute stridor is primarily a clinical one. Acute epiglottitis in children has largely been eradicated in this country courtesy of the HIB vaccination programme but it remains a cause of stridor and odynophagia in adults. *Acute epiglottitis* is primarily a clinical diagnosis and requires prompt treatment. Plain radiography can aid the clinical diagnosis of *acute laryngo-tracheo-bronchitis* / 'croup' demonstrating the characteristic 'steeples', 'pencil tip' or 'wine-bottle' sign caused by narrowing of the subglottic airway on frontal views. Additional features include loss of soft tissue distinction in the glottic region on lateral films, ill-defined haziness at the soft tissue – air interfaces between

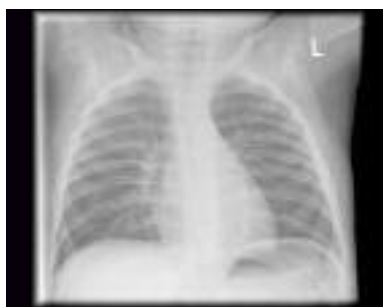

Figure 5: Inspiratory and expiratory chest radiographs showing air-trapping in the left lung on expiratory film.

the glottic and subglottic regions, dilatation of the piriform sinuses and ballooning of the pharynx (Figure 4).

Plain films of the neck can show radio-opaque *inhaled foreign bodies*. When there is clinical suspicion of an inhaled foreign body, inspiratory and expiratory chest radiographs should be obtained and may help to assess for indirect signs of a foreign body in the airway such as air-trapping or lung collapse / consolidation (Figure 5).

Ultrasound of the neck

Ultrasound of the neck is useful in assessing *cystic and solid masses* which may be causing extrinsic compression on the airway. It is also of particular use in imaging the larynx in children, which can be inadequately assessed using CT or MRI due to poor soft tissue contrast. It provides a non-invasive and dynamic mode of imaging without radiation exposure. More recently, laryngeal ultrasound has been used to monitor infants with *vocal fold paralysis*. Abduction-adduction

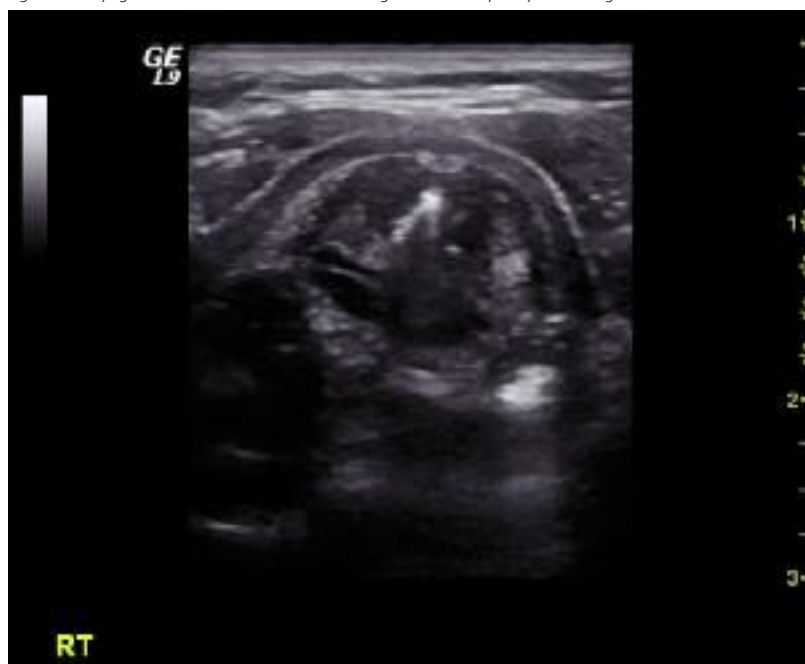movements of the vocal cords can be assessed during deep inspiration and vibration movements during phonation. The resting position of the vocal folds can also be seen (Figure 6).

Ultrasonography can also contribute to the 'work-up' of babies with a laryngeal web, subglottic haemangioma and congenital subglottic stenosis, but endoscopy remains the principal tool for investigation of these conditions.

Fluoroscopy

Contrast swallow is a useful dynamic study but it involves ionising radiation. It can aid in the diagnosis of aspiration, laryngeal cleft, tracheomalacia and tracheo-oesophageal fistula. While pH studies are the investigation of choice for the definitive diagnosis of gastro-oesophageal reflux, contrast swallow examinations can demonstrate reflux into the oesophagus if it occurs during the study although in itself, the contrast swallow is a poor test for detecting reflux. Extrinsic compression from vascular

Figure 6: Laryngeal ultrasound of a child with a right vocal fold paralysis. The right vocal fold is abducted.



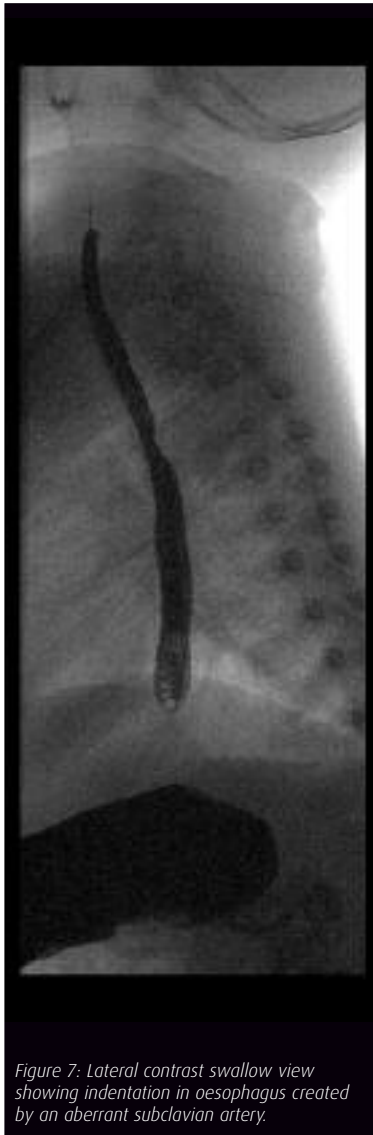

Figure 7: Lateral contrast swallow view showing indentation in oesophagus created by an aberrant subclavian artery.

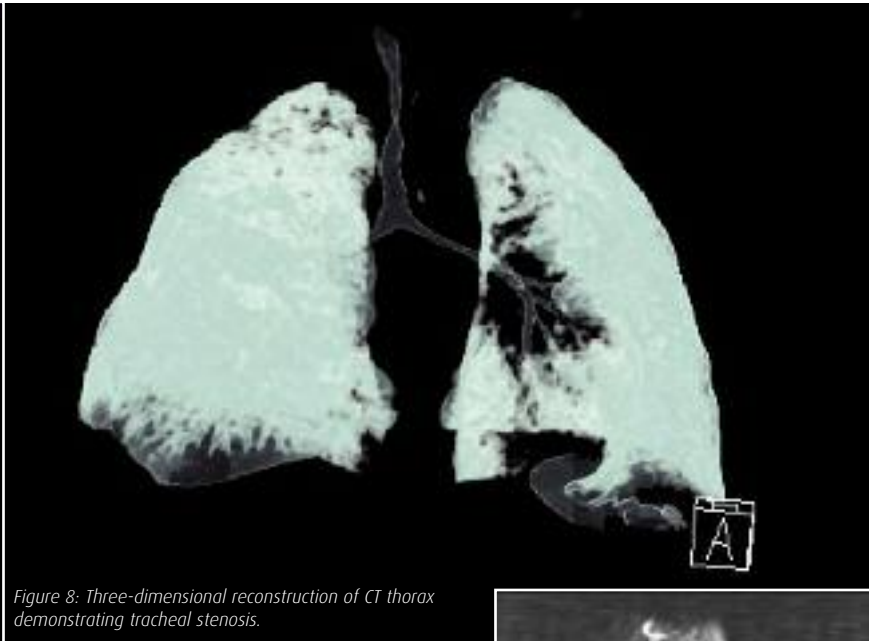


Figure 8: Three-dimensional reconstruction of CT thorax demonstrating tracheal stenosis.

All children with significant stridor should undergo cross sectional imaging with CT or MRI under general anaesthesia

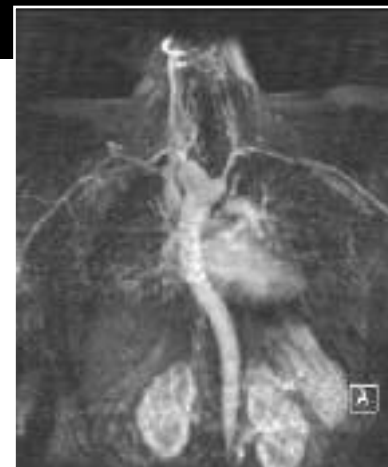

Figure 9: Three-dimensional MIP (maximum intensity projection) post-contrast MRI volume image of the thorax showing double aortic arch.

structures can also be appreciated although further imaging, usually with MRI, is required (Figure 7).

Cross-sectional imaging

Children with significant stridor requiring cross-sectional imaging with CT or MRI should be imaged under general anaesthesia. As an adjunct to airway endoscopy, CT is particularly useful where a tight stenosis prevents safe endoscopic examination distal to the stenosis. In these situations, multidetector CT, especially with 3D reconstruction can define both the luminal diameter as well as the length of the stenosis. Computed Tomography is also beneficial in the further assessment of extra-luminal and thoracic lesions and tumour staging. It is fast and readily accessible but has its limitations due to ionising radiation and requirement for iv contrast which may be contraindicated in certain patients. In the future, spiral CT under controlled ventilation may be used to acquire virtual endoscopy images of the

airway. This may help to replace the more invasive diagnostic methods but the additional ionising radiation exposure needs to be considered. At present, this remains a research tool in development (Figure 8).

MRI is able to easily demonstrate anatomy in the neck and mediastinum in any plane without exposure to ionising radiation or necessarily to contrast media. However, image quality is affected by movement, such as breathing or pulsation artefact from vascular structures so alterations in technique such as respiratory triggered scans are often required. MRI provides detailed imaging of soft tissue structures and vascular anatomy. It has now become accepted as the single most

valuable modality for assessing airway compression, accurately and non-invasively demonstrating the level, severity and cause of airway compression (Figure 9).

Summary

High quality imaging is vital to complement endoscopy in the assessment of the infant with a compromised airway. Safe imaging in the presence of airway compromise requires expertise from radiographers and radiologists but also good communication between the airway surgeon and the radiologist to ensure that the optimal modality is employed to give the necessary clinical information with minimal risk. ■

FURTHER READING

King SJ, Boothroyd AE: *Pediatric ENT Radiology*. Berlin, Germany: Springer-Verlag; 2003.
 Johnson K, Williams H, Foster K, Miller C. *Paediatric Radiology. Oxford Specialist Handbook in Paediatrics*. Oxford, UK: Oxford University Press; 2009.